



Reinforcement of subcuticular continuous suture closure with surgical adhesive strips and gum mastic: is there any additional strength provided?

Reha Yavuzer, M.D.^{a,*}, Christopher Kelly, M.D.^b, Noreen Durrani, M.D.^a,
Vijay Mittal, M.D.^a, Ian T. Jackson, M.D.^b, Stephen Remine, M.D.^a

^aDepartment of Surgery, Providence Hospital and Medical Centers, Southfield, MI, USA

^bInstitute for Craniofacial and Reconstructive Surgery, 16001 W. Nine Mile Rd.–3rd Floor–Fisher Center, Southfield, MI 48075, USA

Manuscript received September 14, 2004; revised manuscript November 19, 2004

Presented at the 47th Annual Meeting of the Midwest Surgical Association, Mackinac Island, Michigan, August 15–18, 2004

Abstract

Background: This study aimed to compare the burst strength of suture closure versus the use of suture and strip together.

Methods: On cadavers, 50 skin incisions were closed as follows: group 1—subcuticular continuous suture; group 2—same suturing with placement of strips; group 3—same as group 2 except gum mastic was applied prior to strips; group 4—strips alone; and group 5—strips with gum mastic application. The separation forces were measured using a tensiometer.

Results: The mean separation forces were as follows: group 1, 14.17 kg; group 2, 14.37 kg; group 3, 15.39 kg; group 4, 1.52 kg; and group 5, 3.85 kg. There were no statistically significant differences between groups 1, 2, and 3. When compared with group 4, group 5 required markedly more force to separate the wound.

Conclusions: Strip reinforcement with/without gum mastic did not provide any additional strength when sutures were used. Gum mastic increased the adherence of strips and this was important when strips were the only means of wound closure. © 2005 Excerpta Medica Inc. All rights reserved.

Keywords: Skin closure; Surgical strip; Tensile strength; Gum mastic

Ideal skin closure should be consistently safe, reliable, easy, and inexpensive, and it should not contribute to complications such as wound infection or foreign body reaction. It should promote healing with as little scarring as possible. Although one of the oldest and easiest ways of wound closure is simple interrupted suturing, this method has the disadvantage of carrying both the epidermis and skin flora along its tract into the wound as it passes through the intact skin. Interrupted sutures can also cause unwanted cross-hatching scars due to tissue swelling, over tightening during suture placement, or late removal of the stitches. A higher incidence of wound infection, as well as a diminished cosmetic outcome, makes this type of closure less preferable. Currently, an absorbable continuous subcuticular suture is frequently used to close surgical incisions [1].

Various problems that have been encountered with the use of sutures encouraged the development of sutureless skin closures such as wound glues or more commonly surgical adhesive strips. The use of surgical strips decreases bacterial proliferation and it has been demonstrated that the bacterial growth underneath the strips was inhibited [2,3]. Tensile strength studies comparing surgical tapes and sutures revealed better results for the taped wounds starting from 10 days postoperatively up to 150 days [4]. Despite the evidence of increased collagen alignment and accelerated epidermal healing, the use of surgical adhesive strips has been limited due to their poor adhesive properties and their potential to cause skin injuries such as blister formation or epidermal stripping [5]. The former is overcome by reinforcement of the strips with chemical adhesives [6]. For the latter, avoidance of excessive tension during application of strips has been recommended. When strips are used as the only means of skin approximation, wound edges tend to be

* Corresponding author. Tel.: +1-248-849-5800; fax: +1-248-849-5881.
E-mail address: ryavuzer@hotmail.com

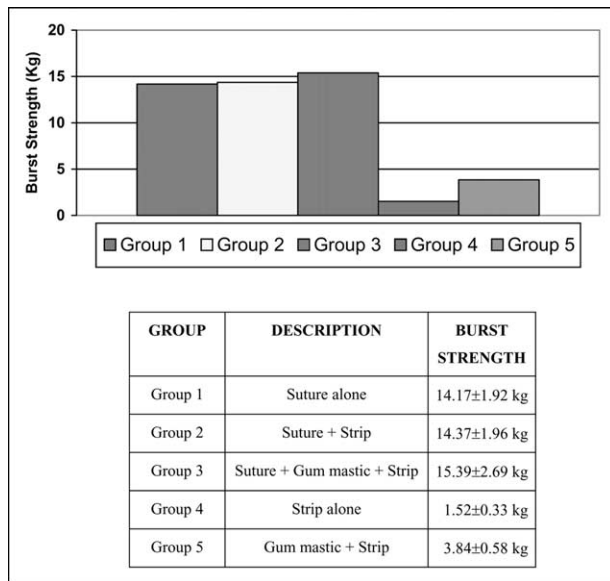


Fig. 1. Mean burst strength values of the groups.

inverted, causing indented scars. In addition, surgical strips alone do not provide enough strength until the healing process has taken place, making early postoperative wound separation likely [1–6].

Surgical adhesive strips, with or without the application of adhesive agents to increase adherence, have been placed over the sutured wounds for various reasons but mainly to decrease the likelihood of unwanted wound separation. However, a recent review revealed that there is no evidence in the literature to confirm the beneficial effects of closing a surgical wound with both absorbable subcuticular sutures and adhesive surgical strips [1].

In this study the burst strength of suture versus suture and strip, with or without gum mastic, was compared to evaluate any beneficial effect of their use in an immediate wound separation model.

Materials and Methods

The backs of 2 fresh-frozen male adult cadavers were used. On each cadaver twenty-five 3-cm, full-thickness skin incisions were created. These 50 incisions were divided into 5 equal groups and approximated as follows: group 1—4/0 absorbable suture (Vicryl; Ethicon, Inc., Johnson & Johnson Co., Somerville, NJ) was used in a continuous subcuticular fashion; group 2—4/0 absorbable suture was used in a continuous subcuticular fashion and, in addition to suturing, 2 surgical adhesive strips (Steri-Strip; 3M, Minnesota Mining and Manufacturing Co., Minneapolis, MN) were placed horizontally; group 3—following the 4/0 absorbable subcuticular continuous suture, the skin was cleaned with an alcohol wipe and then a resinous liquid adhesive, gum mastic (Mastisol; Ferndale Labs, Ferndale, MI) was applied to the skin and left to dry for 3 minutes. This was followed

by transverse placement of surgical strips; group 4—skin approximation was achieved by surgical adhesive strips alone; and group 5—the skin was treated with gum mastic as in group 3 and surgical adhesive strips were applied for skin closure.

In the groups where surgical adhesive strips were used a 3-kg flat weight was placed over the incision for 2 minutes to increase the contact of the strip with skin surface. Thirty minutes were allowed to pass before the measurements were performed on the wounds with strips. The burst strength of each wound was measured by using a tensiometer (PT-DPS-110; Imada Inc., Northbrook, IL) and the force necessary to separate the wounds was recorded.

Analyses were conducted using Statistical Package for the Social Science software (SPSS 11.5 for Windows; SPSS, Inc., Chicago, IL). Kruskal Wallis 1-way analysis of variance was used to compare groups and the Mann-Whitney *U* test was used to evaluate the differences between 2 independent groups. A *P* value of .05 was considered to be statistically significant.

Results

The wounds that were closed with sutures (groups 1, 2, and 3) showed significantly more strength than those that were closed with surgical adhesive strips alone (groups 4 and 5) (Kruskal Wallis test, $P < 0.001$) (Fig. 1). The wounds closed with sutures (groups 1, 2, and 3) showed comparable burst strength values (Kruskal Wallis test, $P = 0.508$) (Fig. 2). Before wound separation occurred in groups 2 and 3, the strips were separated from the skin, which was then followed by wound separation. The strip separation forces (strip peel-off values) of these 2 groups were 4.85 kg and 7.0 kg, respectively (Fig. 3). The difference between the 2 was statistically significant in favor of the gum mastic-treated subjects (Mann-Whitney *U* test, $P = 0.008$). Among wounds closed without sutures, group 5 (gum mastic and strip) required markedly more force to separate the wound than group 4 (strip alone) (Mann-Whitney *U* test, $P = 0.001$) (Fig. 4).

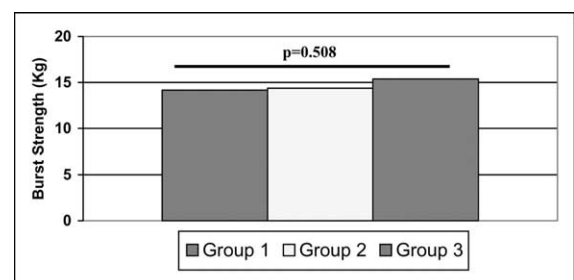


Fig. 2. Comparison of mean burst strength values of sutured groups (groups 1, 2, and 3). There was no statistically significant difference among groups 1, 2, and 3 for burst strength values (Kruskal Wallis test, $P = 0.508$).

Comments

In every surgical procedure, as well as in traumatic skin lacerations, skin approximation is required for proper healing with less scar formation. Throughout the history of medicine many skin closure methods have been tried with the aim of finding the most reliable and easily applicable technique that will also provide the most favorable cosmetic outcome. Wound closure tapes have come into use to decrease tension on wounds closed with sutures, or to reinforce wounds after sutures are removed. Wound closure tapes may be used with additional adhesive materials to increase the adhesive strength. The most commonly used adhesives are compound benzoin tincture and gum mastic. Gum mastic provides an increased adhesiveness when compared to compound benzoin tincture [6,7].

Apart from the adhesive materials, various surgical closure tapes have been also studied regarding the strength that they provide for wound closure. In a study by Moy and Quan, 7 different brands of wound closure tape with or without the additional application of the liquid adhesive gum mastic were compared in an intact human forearm model [8]. These investigators determined that when wound closure tapes are used to reinforce the wound closure, the application of a liquid adhesive such as gum mastic enhances their adhesiveness. They also found that among the 7 wound closure tapes evaluated, Steri-Strips delivered the longest period of adhesiveness provided that gum mastic was also applied.

The use of wound closure tapes has several other proven advantages apart from providing extra tensile strength. When superficial skin wounds are closed with tapes there is an increased rate of healing secondary to an increased rate of cell migration across the wound surface [9]. Surgical tapes have also been shown to inhibit bacterial translocation, decreasing the likelihood of a wound infection. This is directly related to the structural properties of the tape [10–

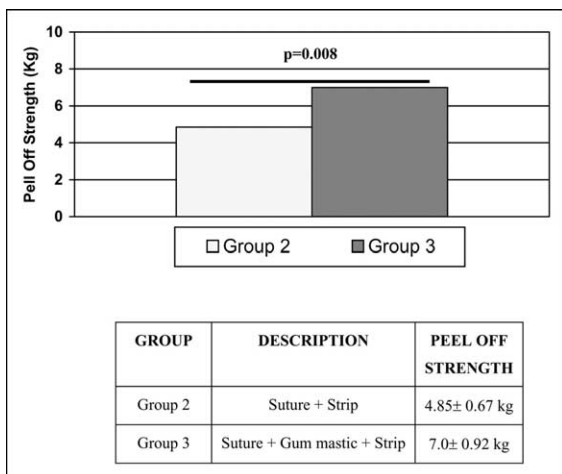


Fig. 3. Mean peel-off strength values of groups 2 and 3 showed a statistically significant difference (Mann-Whitney *U* test, *P* = 0.008).

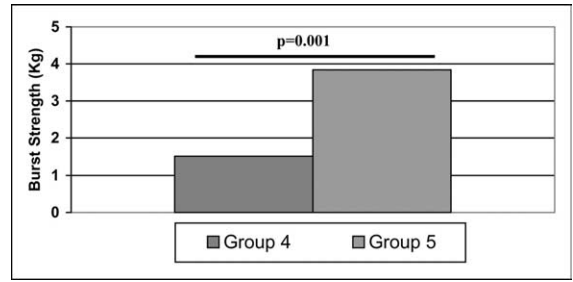


Fig. 4. Comparison of mean burst strength values of sutureless groups (groups 4 and 5). Group 5 (gum mastic and strip) showed markedly more strength than group 4 (strip alone) (Mann-Whitney *U* test, *P* = 0.001).

12]. However, this positive effect seems to be neutralized when adhesive chemicals are used to increase the adhesiveness of the tapes [13]. Surgical tapes also act as an efficient dressing over the incision, eliminating the need for any additional dressing type, especially when no drainage through the incision is expected. This will abolish the cost and time of dressing changes and provide wound coverage that is cosmetically appealing and well accepted by the patient. Despite many studies showing the benefits of surgical tapes, a recent review revealed that no study has compared the use of a combination of subcuticular suture and strip versus strip or subcuticular suture alone [1].

The current study used a fresh cadaver model to adequately compare the strength provided with various closure methods. Although fresh cadavers are possibly one of the best skin models to study tensile strength when compared with animal studies, their use does ignore the healing aspect and only reveals data attributable to the very early postoperative period. However, this is the period when surgical strips provide extra strength for closure in order to avoid early skin dehiscence.

When wound closure was achieved with sutures, no additional strength was provided by reinforcement with either strips alone or gum mastic application and strip placement. Gum mastic significantly increased the adherence of strips and this seems to be especially important when strips are the only means of wound closure. Application of surgical strips over a sutured incision acts to decrease tension across wound and block transient bacterial contamination. However, strip reinforcement did not provide any additional strength in this wound separation model when sutures were used. Further studies involving the healing process are needed to conclude that the use of surgical strips has no positive effect in avoiding early wound separation.

References

- [1] Kolt JD. Use of adhesive surgical tape with the absorbable continuous subcuticular suture. *Aust NZ J Surg* 2003;73:626–9.
- [2] Rodeheaver GT, McLane M, West L, et al. Evaluation of surgical tapes for wound closure. *J Surg Res* 1985;39:251–7.
- [3] Marples RR, Kligman AM. Growth of bacteria under adhesive tapes. *Arch Dermatol* 1969;99:107–10.

- [4] Forrester JC, Zederfeldt BH, Hayes TL, et al. Tape-closed and sutured wounds: a comparison by tensiometry and scanning electron microscopy. *Br J Surg* 1970;57:729–37.
- [5] Blaybock B, Murray M, O'Connell K, et al. Tape injury in the patient with total hip replacement. *Orthop Nurs* 1995;14:25–8.
- [6] Mikhail GR, Selak L, Salo S. Reinforcement of surgical adhesive strips. *J Dermatol Surg Oncol* 1986;12:904–6.
- [7] Mikhail GR, Selak L, Salo S, et al. The efficacy of adhesives in the application of wound dressings. *J Burn Care Rehab* 1989;10:216–9.
- [8] Moy RL, Quan MB. An evaluation of wound closure tapes. *J Dermatol Surg Oncol* 1990;16:721–3.
- [9] Winter GD. Formation of the scap and the rate of its epithelialization of superficial wounds in the skin of the young pig. *Nature* 1962;193:293–4.
- [10] Carpandale MTF, Sereda W. The role of percutaneous suture and surgical wound infection. *Surgery* 1965;58:672–7.
- [11] Schauerhamer RA, Edlich RF, Panek P, et al. Studies in the management of the contaminated wound. VII. Susceptibility of surgical wounds to postoperative surface contamination. *Am J Surg* 1971;122:74–7.
- [12] Marples RR, Kligman AM. Growth of bacteria under adhesive tapes. *Arch Dermatol* 1969;99:107–10.
- [13] Panek PH, Prusak MP, Bolt D, et al. Potentiation of wound infection by adhesive adjuncts. *Am Surg* 1972;38:343–5.